

Indigestible Foreign Bodies in cattle and goats: A veterinary surgical emergency and potential silent killer in South Sudan

Jerves Gibson Friday and Ambrose Jubara*

Department of Clinical Studies, College of Veterinary Science, University of Bahr El-Ghazal.

*Corresponding author. Email: asjubara@yahoo.com

Copyright © 2024 Daniel et al. This article remains permanently open access under the terms of the [Creative Commons Attribution License 4.0](https://creativecommons.org/licenses/by/4.0/), which permits unrestricted use, distribution, and reproduction in any medium, provided the original work is properly cited.

Received 17th November 2023; Accepted 29th January 2024

ABSTRACT: In South Sudan, reckless littering and contamination of environment with all sorts of solid waste turned Indigestible Foreign Bodies (IFBs), poor knowledge of the public and farmers and the current animal husbandry system in practice constituted potential drivers for ruminant animals to inevitably ingest one or more of IFBs, that proved to be a potential, neglected non-infectious disease and a silent killer. The objective of this study was to identify the types and prevalence of IFBs in slaughtered cattle and goats. The research was carried out at two of the biggest slaughterhouses in the towns of Aweil and Wau. This study uses a cross section design in which animals prepared for slaughter were identified at antemortem and their rumen and reticulum were examined for the presence of foreign indigestible bodies. The results show that the overall prevalence of IFBs in both species in the two slaughterhouses was 32.55%, goats were more affected (34.41%) than cattle. Prevalence in aged goats (57.14%) were higher than younger ones. Middle-aged cattle succumbed more (36.11 %) than young ones. Females in both species were more affected (38.04%) than males. Prevalence of IFBs in Aweil municipal slaughterhouse (40.20%) was higher than in Wau slaughterhouse (29.78%). Most recovered types of IFB in cattle and goats were plastics (44.50%) followed by cloths (25.36%). However, mixed type of IFB was the most encountered in goats (68%) than in cattle (31.2%). The study concluded that IFBs ingestion by ruminant animals in South Sudan was widespread but not scientifically documented and disseminated and therefore, recommends extensive public and farmers awareness about solid waste management, type of biodegradables solid wastes and the policymakers to consider classification of IFBs ingestion by ruminant animals as potential non-infectious veterinary emergencies and a silent killer.

Keywords: Cattle, goats, indigestible foreign bodies, prevalence, slaughterhouse.

INTRODUCTION

South Sudan ranked the 7th in the continent given its livestock population of 36 million heads of cattle, sheep, and goats (Musinga *et al.*, 2010). Pastoralism, agro-pastoralism, and free-ranging scavenging management systems were practiced in rural, urban, and peri-urban areas (Musinga *et al.*, 2010).

Indigestible Foreign bodies (IFBs) are materials when ingested by animal cannot be degraded by enzymes, thus cause serious pathological problems. They include plastic

bags, woods, papers, nails, rubbers, rope, nylons, hairs, needles, and cloths (Duresa *et al.*, 2022). Therefore, ingestion of indigestible foreign bodies in cattle is a pathological condition of economic importance which leads to severe economic losses as a result of high morbidity and mortality rates (Mushonga *et al.*, 2015).

Cattle, sheep and goats ingest these materials during periods of drought, food scarcity, nutritional deficiencies (pica) and massive environmental pollution (Omar and Ali



Plate 1. Small ruminants scavenging for food in IFBs polluted environment.

Fara, 2018). Thus, indigestible foreign bodies in the rumen and reticulum of ruminants predisposed by environmental pollution are fast becoming a major global problem in ruminants worldwide (Anwar *et al.*, 2013).

Ingested IFBs are reported to be a common cause of surgical emergency in veterinary medicine (Negash *et al.*, 2015) and is the major non-infectious disease of livestock common in developing countries (Wegi and Urge, 2022). The ingested IFB occupies a space in rumen and reticulum thus reduce feed intake and fattening as it leads to failure of absorption of volatile fatty acids (Sheferaw *et al.*, 2013). It also causes ruminitis, impaction of the rumen, traumatic pericarditis and traumatic reticuloperitonitis and intestinal blockage when it becomes fatal if not removed by surgery (Gugjoo *et al.*, 2021). Carcasses and offal of affected animal are downgraded or outright condemned (Nongcula *et al.*, 2017).

Ingestible Foreign Bodies in gastro intestinal tract are diagnosed by palpation, exploratory surgery, ultrasonography, radiology or at necropsy (Mozaffari *et al.*, 2009; Semieka *et al.*, 2010; Ramaswamy and Sharma, 2011; Nugusu *et al.*, 2013).

Many authors have reported incidences of Indigestible Foreign Bodies in their countries such as Otsyina *et al.*

(2015) in Kenya, and in Ethiopia (Wegi and Urge, 2022; Tesfaye and Chanie, 2012; Duresa *et al.*, 2022), Nigeria (Igbokwe *et al.*, 2003; Remi-Adewunmi *et al.*, 2004; Rabana *et al.*, 2022), in Sudan (Hayder *et al.*, 2006), Egypt (Semieka, 2010), Somalia (Shair *et al.*, 2023), Rowanda (Mushonga *et al.*, 2015), Tanzania (Bwatota *et al.*, 2018) and in Spain (Martin *et al.*, 2021).

In South Sudan, rapid urban sprawl and infrastructural development was observed following independence in the year 2011. Its booming economy made it to become a lucrative market for commodities, building materials from countries within and outside the region. This coupled with lack of culture and system for solid waste management, led to wide spread littering of rural and urban environment with most types of Indigestible Foreign Bodies and consequence of severe environment pollution (Plate 1).

Unavailability of diagnostic facilities and unawareness of animals' owners about the pathogenesis of IFB, in addition to surgical intervention as the only treatment method (Plate 2), exacerbated morbidity and mortality rates of livestock due to IFBs.

Several municipal orders for banning plastic bags and observance of environmental hygiene were issued without solid knowledge of the magnitude of impact on animal

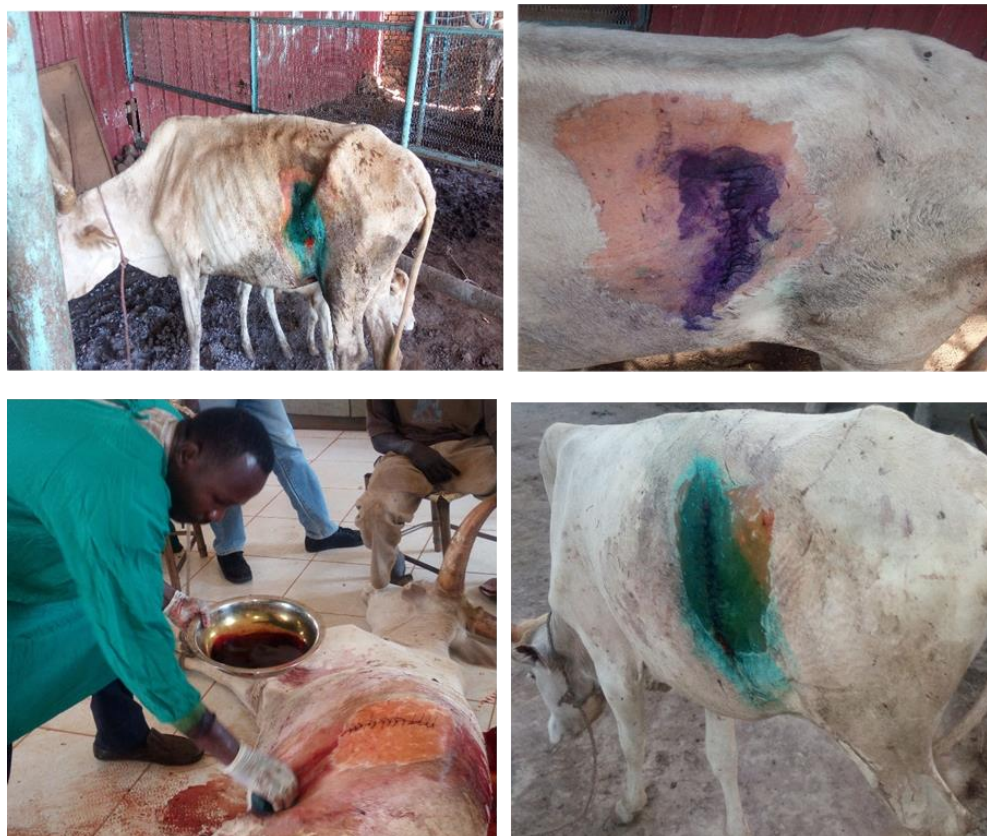

Plate 2. Surgical procedures for removal of IFBs from two weeks post-partum cow in clinic of college of Veterinary Science, University of Bahr el Ghazal.

health and production as there is no research data that depicts the extend of this silent killer among ruminants' species in the country. Therefore, this study was carried out to document prevalence and types of IFBs in slaughtered cattle and goats in two major abattoirs in two states of greater Bahr El-Ghazal Region and to correlate frequency of occurrence with animal species, age and gender.

MATERIALS AND METHODS

Study area

The study was conducted in Aweil and Wau Municipalities (Figure 1). **Aweil Municipality** is a city and the capital of the Northern Bahr el-Ghazal State, located in northwestern South Sudan near the international border with the Republic of Sudan and the Abyei Administrative Area. This location lies approximately 800 km (500 miles) by road northwest of Juba, the capital and largest city in the country. The coordinates of Aweil are: 8°46' 02.00" N, 27° 23' 59.00" E (latitude: 8.7671; longitude: 27.3998). In Aweil the study site includes Aweil Livestock Auction where all

ante-mortem examinations were carried out and Aweil slaughter house in which cross-sectional studies was conducted.

Wau Municipality is a city in northwestern South Sudan, on the western bank of Jur River, which serves as capital city for Western Bahr el Ghazal State. It lies approximately 650 km (400 miles) northwest of the capital Juba. A culturally, ethnically, linguistically diverse urban center and trading hub. The coordinates of Wau are: 7°42'00N, 28°00'00 E. In Wau the area of study includes Eastern Bank Livestock Market where goats were purchased for surgical operation, Surgical theatre in the College of Veterinary Science at University of Bahr El-Ghazal where rumenotomy operations were carried out, Lokloko slaughterhouse where the cross-sectional studies were conducted.

Study animals

The study was conducted on cattle and goats of local Nilotic breeds mainly originated from NBG, Warrap and WBG States of greater Bahr el Ghazal. The studies were conducted on both sexes and different ages from the two

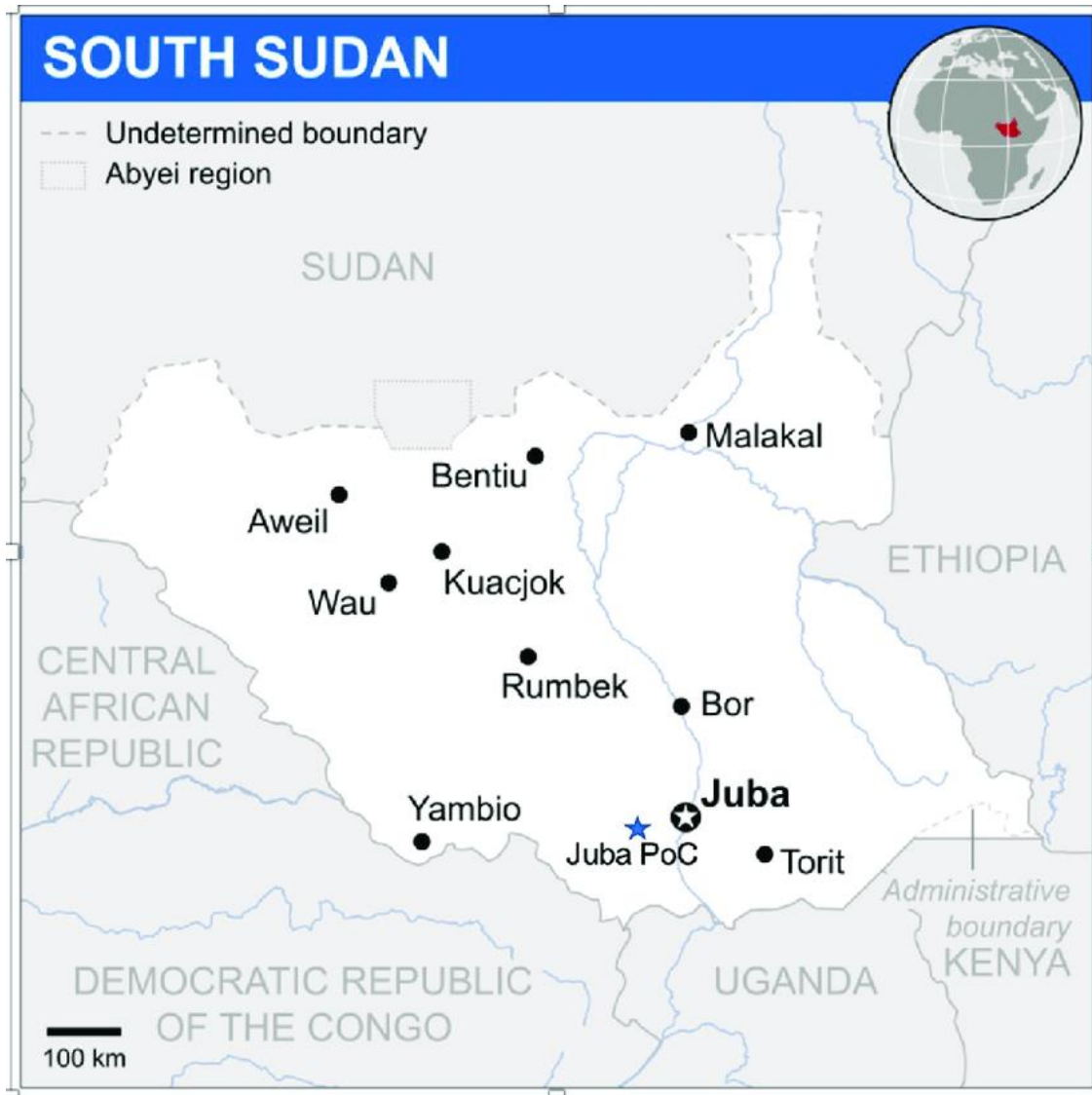

Figure 1. Map indicating study areas (Aweil and Wau) in greater Bahr El-Ghazal Region of South Sudan.

species. Slaughtered animals (n=344) were randomly selected at the slaughterhouses of Aweil and Wau, consisted of 217 goats and 127 cattle. Although sheep can be affected, they were not included in the study because only few numbers were turned for slaughter.

Determination of sample size

The sample size required for prevalence study was determined based on sample size determination in random sampling for infinite population using expected prevalence of rumen Indigestible Foreign Bodies in cattle and goats and the desired absolute precision according to Thrusfield (1986) as follows:

$$n = \frac{(1.96)^2 P_{exp}(1-P_{exp})}{d^2}$$

or $N = z^2 p(1-p)/d^2$

Where: n = required sample size, P_{exp} = expected prevalence, d =desired absolute precision, N = sample size, Z = statistic corresponding to level of confidence, P = expected prevalence.

The calculated sample size for this study was determined using 50% expected prevalence as there was no prior report of IFB prevalence in the country. Therefore, using 50% expected prevalence and 5% absolute precision at 95% confidence level using the above formula, the sample



Plate 3. Different types of impacted foreign bodies exteriorized from rumen and reticulum of cattle.



Plate 4. Foreign bodies after being washed contain plastic bags.

size was determined to be 384 ruminants (cattle and goats) were examined. However, 344 samples were collected for the study instead of 384.

Study design

Cross-sectional investigation was conducted for the prevalence and the identification of indigestible foreign bodies (Duresa *et al.*, 2022). Prior to post mortem and the antemortem, animals' species, sex and age were assessed. Age assessment was carried out to estimate the ages of the animals selected for the study, sex of each animal was observed, body weights was determined using spring scale for goats and measuring tape for cattle. All the animals were ear marked and given special identification code for easy identification and collection of their internal

organs being gathered for cross-sectional study. At postmortem, the four chambers of stomach were thoroughly palpated, incised, and any non-food items that were found were removed, labeled, washed and dried, then sorted for verification of IFB type (Plates 3 and 4).

Data collection

The data collected were for both animals' information and foreign bodies information for all animals in this study. The data collected include animal information such as sex, age, and weight for each animal at ante mortem and indigestible foreign bodies data to confirm presence of foreign bodies in each slaughtered animal, weight of foreign bodies before and after washing, and type of foreign bodies.

Data management and analysis

All goats and cattle that were selected for the study were identified by a unique identification code. Each animal was registered against its location, species, age, sex, and body weight. The IFBs obtained were recorded in accordance to location, sex, age of the animals, and the types of foreign bodies obtained were recorded in accordance to their frequency of occurrence. The data collected were managed using computer-based data management system (MS excel 2010 and SPSS version 20). For data analysis, descriptive statistics was used. Prevalence of indigestible foreign body was stated as the number of cases of foreign bodies found to the total number of animals examined in this study. A different analysis was carried out on the prevalence of foreign body across the two species (cattle and goat). The effect of location, sex, and age on the occurrence of the disease was also tested.

Ethical considerations

The study was first approved by the Institutional Ethical Committee of the University of Bahr El-Ghazal vide approval letter No. UBG -IEC 11/2023/02, and also by the State Ministry of Animal Resource and Fisheries (MARF) Wau and Aweil, South Sudan.

RESULTS

Overall prevalence of Indigestible Foreign Bodies (IFBs) n=344

Of the 344 ruminants (217 goats and 127 cattle) studied for the presence of foreign indigestible materials in their rumen and reticulum, the overall prevalence was 31.40% (108) with the prevalence of 23.62% (30) and 35.94% (78) among cattle and goats respectively. The data presented were from abattoir studies (n=344) in Aweil and Wau respectively. Figure 2 depicts overall prevalence of IFBs in slaughtered goats in Wau and Aweil is higher than that of cattle.

Prevalence of IFBs according to the location (n=344)

Out of total sample size, 242 cattle and goat were slaughtered in Wau and 102 slaughtered cattle and goats in Aweil. As shown in Figure 3, the prevalence of IFBs was higher among ruminants slaughtered in Aweil Municipality compare to those slaughtered in Wau (40.20%, 27.70%,) respectively.

Prevalence of IFBs as per animal species slaughtered in Aweil Municipal Abattoir (n=102)

Total animals slaughtered at Aweil were 102 animals (57

cattle and 45 goats). Prevalence of IFBs among different species were 18 (31.57%) and 23 (51.11%) for bovine and caprine respectively. Caprine species showed the highest prevalence compared to bovine as shown in Table 1.

Prevalence of IFBs as per animal species slaughtered at Lokloko in Wau Municipal Slaughterhouse

Number of animals slaughtered at Wau were 242 animals (70 cattle and 172 goats). Prevalence of IFBs among different species was 12 (17.14%) and 55 (31.98%) for bovine and caprine respectively. Caprine species showed the highest prevalence compared to bovine as shown in Table (2).

Prevalence of IFBs in slaughtered cattle and goats according to their sex (n=344)

The number of animals slaughtered at both Aweil and Wau slaughter houses is 344 of which males were 164 and 180 females, as shown in the Figure 4. The recorded prevalence was 26.82% among male ruminants and 35.55% among females.

Prevalence of IFB in cattle and goats according to age groups

All the examined cattle and goats were categorized into different age categories, for goats they were categorized to 1-3, 3-8, and >8 years and the number of goats examined per each category was 116, 94, and 7 for the foreign bodies, respectively. However, the prevalence rates were high amongst older goats as shown in Table 3. Age categories of cattle were 2-6, 7-10 and >10 years, and prevalence was observed at 22.36%, 32.35% and 11.76% in cattle of 2-6 years, 7-10 years and >10 years old, respectively. Unlike goats, the prevalence of indigestible foreign materials in the older categories was higher than in younger, for cattle, high prevalence was recorded in middle ages animals, followed by younger ages and then the older (Table 4).

Types of IFBs in slaughtered cattle and goats in both Wau and Aweil

The frequencies of different types of indigestible foreign materials found in goats and cattle in Aweil and Wau Municipalities were plastics 83 (46.36%), clothing materials 44 (24.58%), rope 16 (8.93%), nylon 14 (7.82%), hair ball 12 (6.70%), mosquito net 6 (3.35%), metal 1 (0.55%) and leather was found nil (Figure 5).

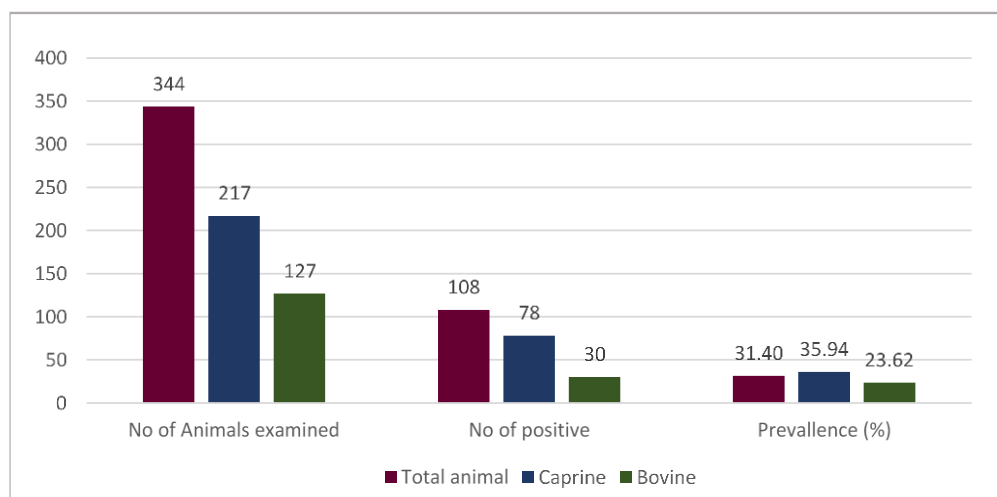


Figure 2. Over all prevalence of indigestible foreign bodies for both goats and cattle in the study areas.

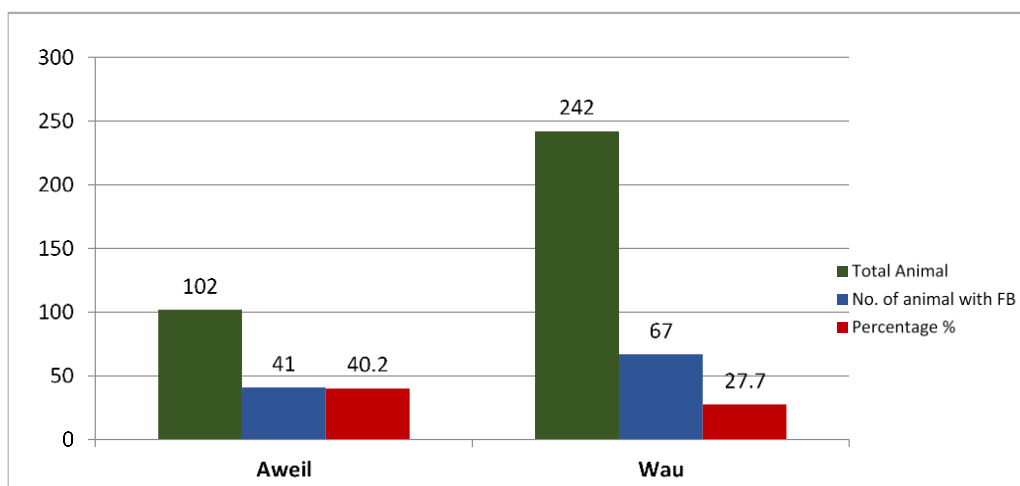


Figure 3. Prevalence of indigestible foreign bodies for the studied animals (goats and cattle) as per study area.

Table 1. Prevalence of IFBs by animal species in animal slaughtered in Aweil (n=102).

Species	No. of studied animals	No. of Animal with F.B.	Prevalence %
Bovine	57	18	31.58
Caprine	45	23	51.11
Total	102	41	40.20

Table 2. Prevalence of IFBs by animals species in animal slaughtered at Lokloko-Wau (n=242).

Species	No. of studied animals	No. of Animal with F.B.	Prevalence (%)
Cattle	70	12	17.14
Goats	172	55	31.98
Total	242	67	27.69

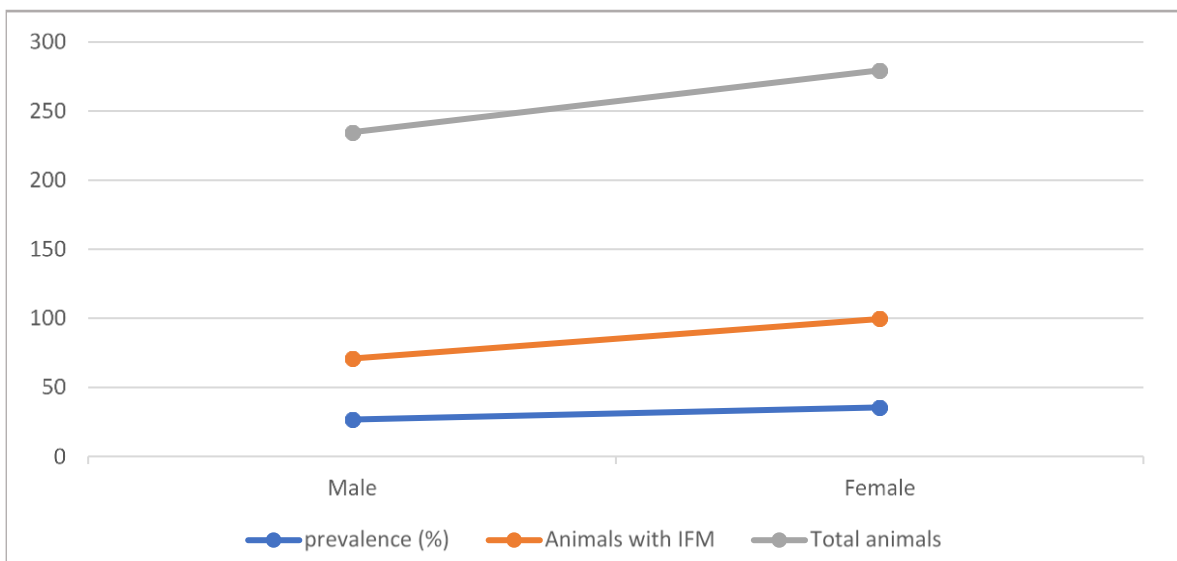


Figure 4. Prevalence of IFMs among slaughtered cattle and goats according to their sex.

Table 3. Prevalence of IFBs in goats according to their age categories (n=217).

Age (years)	No. of studied goats	No. of goats with F.B.	Prevalence %
1-3	116	39	33.62
>3-8	94	35	37.23
>8	7	4	57.14
Total	217	78	35.94

Table 4. Prevalence of IFBs in cattle according to their age categories (n=127).

Age (years)	No. of studied cattle	No. of cattle with F.B.	Prevalence %
2-6	76	17	22.36
7-10	34	11	32.35
>10	17	2	11.76
Total	127	30	23.62

Frequency of IFBs types in cattle and goats according to sex (n=344)

Among the 108 positive cases of indigestible foreign bodies, the highest frequency was for mixture materials 50 (16: male, 34: female) and plastics 37 (16: male, 21: female) (Table 5), followed by clothing materials 14 (8: male, 6: female), hair ball 5 (3: male, 2: female), and rope 2 (1: male, 1: female). The mixture materials and plastics are more found in females than male animals. And clothing materials and hair ball were found higher in male animals than in female while ingested ropes were found to be 1 in both sexes.

Various types of IFBs in goats and cattle by the location of the study

The magnitude and frequency of different types of IFB were assessed in cattle and goats. Goats were highly exposed to all types of IFB (22.67%) than cattle which were highly exposed to clothes (8.72%) as shown in Table 6.

Prevalence of IFB according to their types and animal age

In goats, the total percentage of hairball and mixed foreign bodies were more observed in young animals, plastics

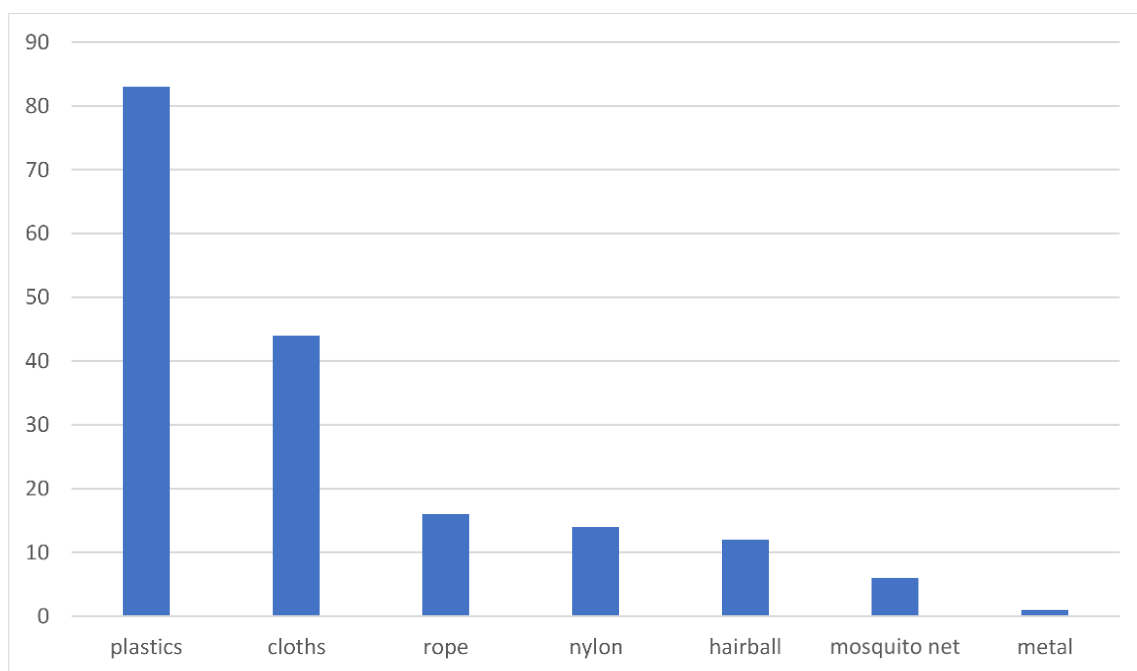


Figure 5. Different types of IFB found in the digestive tract of cattle and goats in the study areas.

Table 5. Frequency of IFBs types according to the animal sex.

Nature (type) of the foreign body	Animal's gender		Total (positive animals)
	Male	Female	
Cloth	8	6	14
Plastic	16	21	37
Nylon	-	-	-
Hair Ball	3	2	5
Rope	1	1	2
Mixed	16	34	50
Total	179	205	344
Positive	44	64	108
Percentage (%)	12.79	18.60	31.39

Table 6. Various types of IFBs in different animal species.

Nature of the foreign body	Species of animal		Total (positive animals)
	Cattle	Goats	
Cloth	8	6	14
Plastic	10	27	37
Nylon	-	-	-
Hair Ball	1	4	5
Rope	-	2	2
Mixed	11	39	50
Total	127	217	344
Positive	30	78	108
Percentage (%)	8.72	22.67	31.39

Table 7. Frequency of IFB type in goats age group.

Nature of the foreign body	Age group by year			Total (positive animals)
	Young (1-3)	Adult (>3-8)	Old (>8)	
Cloth	3	3	-	6
Plastic	12	13	2	27
Hair Ball	4	-	-	4
Rope	1	1	-	2
Mixed	26	13	-	39
Total	39	35	4	78
Percentage (%)	11.33	10.17	1.16	22.67

Table 8. Frequency of IFB types in cattle age group (n=344).

Nature of the foreign body	Age group by year			Total
	Young (2-6)	Adult (7-10)	Old (>10)	
Cloth	4	3	-	8
Plastic	6	4	-	10
Hair Ball	-	-	1	1
Mixed	7	4	1	21
Total	17	11	2	40
Percentage (%)	62.50	32.50	5.00	100

were more in adults, and cloths and ropes were equally found in young and adult goats as shown in the Table 7. In cattle, total percentage of different IFBs were more observed in young cattle, followed by adults, and old with less as stated in the Table 8.

DISCUSSION

Ingestion of Indigestible Foreign Bodies (IFBs) by ruminant animals in South Sudan (Plate 1), though sporadic, became a known policy neglected silent killer, with substantial financial losses incurred by the animal owners. Although worldwide evidence shows that plastic bags are non-degradable and thus damage the environment especially grazing and agricultural lands, waterways, this study in South Sudan remains the first empirical evidence of damages caused by plastics materials on ruminant animals. Furthermore, it stands as the scientific proof to the magnitude of IFBs impact on animals and therefore invites policies for control.

This study showed that, the overall prevalence of IFB affection in cattle and goats (32.55%) is in line with the findings of Duresa *et al.* (2022) who reported an overall prevalence of 30.73%. But disagreed with the higher prevalence (52.1%) reported by Negash *et al.* (2015) and 41.7% reported by Amin and Fentahun (2020), and the lower prevalence of 23.4% and 21.8% reported by Sitotaw *et al.* (2017) and Teshome *et al.* (2017), respectively. The

discrepancy could be due to the number of animals studied, the duration of study, degree of pollution or animal exposure, and availability of fodders.

In the current study, goats are more affected (34.41%) compared to cattle (23.62%). This may be attributed to fact that, goats are more scavengers than cattle. However, high prevalence of 40%, 59.3%, 43.4%, of IFBs affections were reported else where in goats by Omar and Ali Fara (2018). Lower prevalence (11.9%) of ingestion of IFBs in goats was also reported by Sheferaw *et al.* (2014). Nevertheless, in a separate studies on goats and sheep in Nigeria, South Darfur, Eastern Ethiopia and Somalia, a prevalence rate of 95%, 87%, 79% and 58.1% of IFBs affections were reported by Fasil (2016), Ghurashi *et al.* (2009), Shair *et al.* (2023) and Negash *et al.* (2015), respectively.

The prevalence of IFBs in cattle during this study period was 29.20%. It seem that it is the lowest prevalence recorded when compared to prevalence of 43.4%, 41.8%, 35.7%, 63% and 64.8%, and 59.14% reported by Seifu *et al.* (2015), Sheferaw *et al.* (2014), Mekuanint *et al.* (2017) Nongcula *et al.* (2017), and Anwar *et al.* (2013), respectively. However, this prevalence was higher than 24.03%, 17.4% and 12% revealed by Bwatota *et al.* (2018) in Tanzania, Mushonga *et al.* (2015) in Rwanda and Akinbobola *et al.* (2016) in Nigeria, respectively.

Increased percentage of IFBs (40.20%) in slaughtered animals reported in Aweil Municipality than Wau (27.69%) (Tables 1 and 2). This discrepancy is due to the fact that,

majority of animals in Aweil are reared in urban and peri-urban settings where no proper solid waste disposal being practiced. Similarly a high prevalence were reported in Ethiopia 43.4% and Pakistan 59.14% by Seifu *et al.* (2015) and Anwar *et al.* (2013), respectively. However, the prevalence (29.80%) reported in Wau Municipality (Figure 2) was even higher than the 24.03%, 17.4% and 12% reported in Tanzania, Rwanda and Nigeria by Bwatota *et al.* (2018), Mushonga *et al.* (2015), and Akinbobola *et al.* (2016), respectively.

Prevalence of IFB is more common in aged animals than younger ones. It was 57.14% higher in goats >8 years and 36.11% higher in cattle aged 6-10 years. Female cattle and goats are more susceptible to IFB than males. In South Sudan, laws prohibiting slaughter of female, appeared to be not strictly adhered to. The results obtained in this study were in agreement with that of Tesfaye and Chanie (2012), Amin and Fentahun (2020), Bwatota *et al.* (2018) and Teshome *et al.* (2017).

Types of IFBs recovered from slaughtered animals are plastics, clothes, ropes, leathers, nylon, polybezoars and mixture of all of these IFBs. Although plastic is the most encountered in cattle and goats (44.50%) followed by clothes (25.36%), goats are exposed almost to all types of IFBs (68%) compared to cattle which mostly exposed to clothes and plastic (31.2%). Many studies simulate the present study in ranking plastic and clothes as the most notorious IFB in cattle, sheep and goat (Amin and Fentahun, 2020; Bwatota *et al.*, 2018; Igboke *et al.*, 2003; Hailat, 1997; Sitotaw *et al.*, 2017; Nongcula *et al.*, 2017). However, Omar and Ali Fara (2018) encountered (13.4%) as the highest prevalence of mixed type of IFB among small ruminants in Somalia. It is worth noting in this study that, there seem to be a strong correlation between the age and species of an animal and the type of IFB prevalence. This observation however may require a separate investigation.

Conclusions and Recommendations

During the seven months study period in the two Municipalities, the overall prevalence of IFB affection among the two species was 32.55%. The prevalence was higher in goats (34.41%). Aweil Municipality recorded the highest prevalence (40.20%) than Wau (29.78%). Females of both species were mostly affected (38.04%) and that aged goats sustained high prevalence (57.14%) and cattle of middle age succumbed to IFB more than the older ones (36.11%). Different types of IFBs were found in goats, while clothes were common in cattle. The pathophysiology of IFBs in ruminants incurred financial losses to the animals' owner when the animals suddenly died, became emaciated or the cost incurred when referred for surgical operation.

Based on the conclusion above, the study recommends

the following:

1. Policy makers to include control of IFB in the national list of diseases to be control and to formulate a legally binding regulations towards reducing environmental pollution.
2. Public education and enlightenment of the citizen in the study areas about reckless disposal of plastic bags, rope, clothes and leather so as to minimizing environmental pollution with plastic materials, cloth, that livestock owner should be aware of the risk to animals' graze on polluted environment with indigestible foreign materials.
3. Devise a policy to revisiting the current animal husbandry system around villages, urban and peri-urban areas.
4. Adoption of proper waste disposal practices, and establishment of good recycling system.
5. Minimize the exposure of animals to ingestion of IFBs by provision of minerals supplement.
6. Improvement of diagnostic methods and facilities for prompt surgical removal of IFB.
7. Further studies should be conducted to determine biochemical, pathological effects of IFBs in animals and the leaching of micro-plastic into meat and milk for human consumption.

COMPETING INTERESTS

The authors declare that there is no conflict of interest. All the step from data collection, writing to publication were carried out with consents of authors.

ACKNOWLEDGEMENTS

The authors are very much thankful to authorities in the State Ministries of Animal Resources in Aweil and Wau for permitting conduct of this research. Our sincere appreciation to the technicians who help greatly in data collection. Special thanks to those who contributed to fine tune this manuscript.

REFERENCES

- Amin, I., & Fentahun, T. (2020). Postmortem study on indigestible foreign bodies in rumen and reticulum of cattle (case: Haramaya and Awaday municipal abattoirs, Eastern Ethiopia). *Online Journal of Animal and Feed Research*, 10(4), 172-179.
- Anwar, K., Khan, I., Aslam, A., Mujtaba, M., Din, A., Amin, Y., & Ali, Z. (2013). Prevalence of indigestible rumen and reticulum foreign bodies in Achai cattle at different regions of Khyber Pakhtunkhwa. *ARPN Journal of Agricultural and Biological Science*, 8(8), 580-586.

- Bwatota, S. F., Makungu, M., & Nonga, H. E. (2018). Occurrences of indigestible foreign bodies in cattle slaughtered at Morogoro Municipal Slaughterhouse, Tanzania. *Journal of Veterinary Medicine*, Volume 2018, Article ID 4818203, 6 pages.
- Duresa, L. A., Kitessa, J. D., & Feyissa, C. T. (2022). Prevalence of indigestible foreign bodies and its associated potential risk factors in rumen and reticulum of domestic ruminants at Bishoftu Elfora Export Abattoir. *Veterinary Medicine and Science*, 8(6), 2623-2630.
- Fasil, N. (2016). Assessment of sheep and goat foreign bodies in rumen and reticulum in the Jigjiga municipal Abattiar. *Journal of Advances in Dairy Research*, 4(3), 157.
- Ghurashi, M. A. H., Seri, H. I., Bakheit, A. H., & Ashwag, E. A. M. (2009). Effect of surgical removal of foreign body from goat's rumen with special reference to the prevalence of foreign body in goats in Southern Darfur. *Australian Journal of Basic and Applied Sciences*, 3(2), 664-668.
- Gugjoo, M. B., Dar, S. H., Ahmad, R. A., Hussain, H. A., Dar, M. D., Jalal-Ud-Din, P., & Dhama, K. (2021). Traumatic reticuloperitonitis in cattle and buffalo: Recent advances in understanding of etiopathogenesis, diagnosis and treatment. *The Indian Journal of Animal Sciences*, 91(11), 895-905.
- Hailat, N., Nouh, S., Al-Darraj, A., Lafi, S., Al-Ani, F., & Al-Majali, A. (1997). Prevalence and pathology of foreign bodies (plastics) in Awassi sheep in Jordan. *Small Ruminant Research*, 24(1), 43-48.
- Hayder, A. M., Bakhiet, A. O., & Mohammed, A. A. (2006). Retrospective study on the prevalence of foreign body in goats' rumen: Omdurman Province, Khartoum State, Sudan (1998–2002). *Journal of Animal and Veterinary Advances*, 5(6), 449-451.
- Igbokwe, I. O., Kolo, M. Y., & Egwu, G. O. (2003). Rumen impaction in sheep with indigestible foreign bodies in the semi-arid region of Nigeria. *Small Ruminant Research*, 49(2), 141-146.
- Martin, S., López, A. M., Morales, M., Morales, I., Tejedor-Junco, M. T., & Corbera, J. A. (2021). Rumenotomy in small ruminants—a review. *Journal of Applied Animal Research*, 49(1), 104-108.
- Mozaffari, A. A., Olomi, M. M., & Vosough, D. (2009). Unusual and severe ruminal impaction in a goat-kid: Clinical and radiological findings. *Iranian Journal of Veterinary Surgery*, 4(1-2), 115-119.
- Mushonga, B., Habarugira, G., Musabyemungu, A., Udahemuka, J. C., Jaja, F. I., & Pepe, D. (2015). Investigations of foreign bodies in the fore-stomach of cattle at Ngoma Slaughterhouse, Rwanda. *Journal of the South African Veterinary Association*, 86(1), 1-6.
- Musinga, M., Gathuma, J. M., Engorok, O., & Dargie, T. H. (2010). The Livestock Sector in Southern Sudan: Results of a Value Chain Study of the Livestock Sector in Five States of Southern Sudan Covered by MDTF with a Focus on Red Meat. *The Netherlands Development Organization*.
- Negash, S., Sheferaw, D., & Sibhat, B. (2015). A postmortem study on indigestible foreign bodies in the rumen and reticulum of ruminants, eastern Ethiopia. *Onderstepoort Journal of Veterinary Research*, 82(1), 5 pages.
- Nongcula, V. V., Zhou, L., Nhundu, K., & Jaja, I. F. (2017). Association between the prevalence of indigestible foreign objects in the gastrointestinal tract of slaughtered cattle and body condition score. *Animals*, 7(11), 80.
- Nugusu, S., Velappagounder, R., Unakal, C., & Nagappan, R. (2013). Studies on foreign body ingestion and their related complications in ruminants associated with inappropriate solid waste disposal in Gondar Town, North West Ethiopia. *International Journal of Animal and Veterinary Advances*, 5(2), 67-74.
- Omar, A. M., & Ali Fara, A. A. (2018). Ingestion foreign bodies in rumen and reticulum of shoats in Hargeisa, Somalia: Prevalence and the associated risk factors. *Archives of Dairy Research and Technology*, ADRT-106
- Otsyina, H. R., Nguhiu-Mwangi, J., Mogo, E. G. M., Mbutia, P. G., & Ogara, W. O. (2015). Prevalence of indigestible rumen foreign bodies in sheep and goats at Dagoretti and Kiserian Abattoirs, Kenya. *International Journal of Veterinary Science*, 4(2), 75-80
- Rabana, L. J., Bukola, Y. Z., Mustapha, M., & Adamu, L. (2022). Indigestible Foreign Materials Impaction of Small Ruminants in Gombe State, Nigeria. *Iranian Journal of Veterinary Medicine*, 16(1), 1-14.
- Ramaswamy, V., & Sharma, H. R. (2011). Plastic bags—Threat to environment and cattle health: A retrospective study from Gondar City of Ethiopia. *The IIOAB Journal*, 2(1), 6-11.
- Remi-Adewunmi, B. D., Gyang, E. O., & Osinowo, A. O. (2004). Abattoir survey of foreign body rumen impaction small ruminants. *Nigerian Veterinary Journal*, 25(2), 32-38.
- Semieka, M. A. (2010). Radiography of unusual foreign body in ruminants. *Veterinary World*, 3(10), 473-475.
- Shair, M. A., Hassan-Kadle, A. A., Osman, A. M., Ahmed, K. M., Yusuf, A. A., Barros-Filho, I. R., & Vieira, R. F. (2023). Indigestible foreign bodies in the forestomach of slaughtered goats in Mogadishu, Somalia. *Veterinary World*, 16(9), 1829-1832.
- Sheferaw, D., Gebru, F., Asrat, M., Tesfaye, D., & Debela, E. (2014). Ingestion of indigestible foreign materials by free grazing ruminants in Amhara Region, Ethiopia. *Tropical animal Health and Production*, 46, 247-250.
- Sitotaw, M., Alemneh, T., & Arsedie, T. (2017). Indigestible Rumen Foreign Bodies—Causes of Rumen Impaction in Cattle, Sheep and Goats Slaughtered at Addis Ababa Abattoir Enterprise, Ethiopia.
- Tesfaye, D., & Chanie, M. (2012). Study on rumen and reticulum foreign bodies in cattle slaughtered at Jimma Municipal Abattoir, South West Ethiopia. *American-Eurasian Journal of Scientific Research*, 7(4), 160-167.
- Teshome, E., Abdela, N., & Hassan, A. (2017). Postmortem study on indigestible foreign bodies in rumen and reticulum of ruminants slaughtered at Asella Municipal Abattoir, Southeastern Ethiopia. *Journal of Veterinary Science & Technology*, 8, 436.
- Thrusfield, M. (1986). 3 - Some general epidemiological concepts. In : *Veterinary Epidemiology*. Pp. 20-29.
- Wegi, F. G., & Urge, B. (2022). Surgical removal of indigestible foreign bodies in cattle and economic losses to farmers. *American Journal of Zoology*, 5(1), 7-10.